
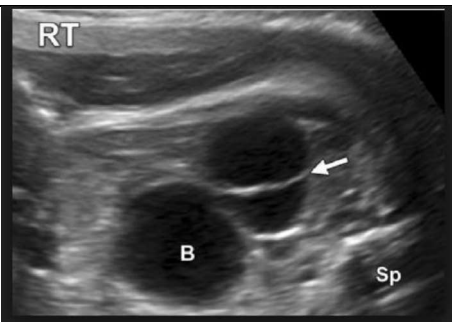
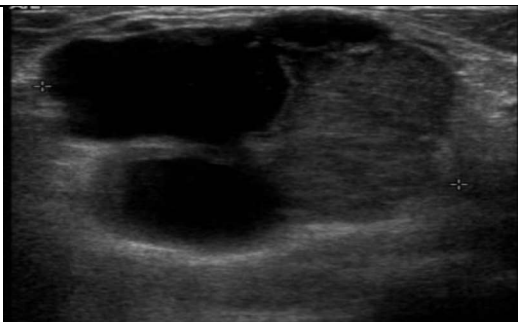


Imaging Controlled Document

Ultrasound Protocols

Renal cysts.

Type of cyst	Simple renal cyst.	Renal cyst with 1 single thin septation.	Complicated renal cyst.
Image.			
Description.	<ul style="list-style-type: none"> - Anechoic, - Thin walled, - Posterior acoustic enhancement. 	<ul style="list-style-type: none"> - Anechoic renal cyst. - One thin septation. - No PMH of malignancy. - No reason for concern. - No calcification. 	<ul style="list-style-type: none"> - Irregular outline. - Thick wall. - Internal septations. - Echogenic material present.
Action.	<ul style="list-style-type: none"> - Document number of cysts, size, appearance and location on the radiology report. 	<ul style="list-style-type: none"> - Document size, appearance and location on the radiology report. 	<ul style="list-style-type: none"> - Document appearance on radiology report including measurements and location.
Follow up.	<ul style="list-style-type: none"> - No further follow-up is needed. 	<ul style="list-style-type: none"> - No further follow-up is needed. 	<ul style="list-style-type: none"> - Seek advice from renal radiologist, to aid patient management.

Document Name:	Author:	Issue Date:
USprotocolkidneys	Dr Riley.	26/09/19
Version:	Authorised By:	Review Date:
2.0	Clair Powell	26/09/22
\\uhb\userdata\imaging\XRAY\common\MODALITY SYSTEMS OF WORK\ULTRASO ND\3 WORK INSTRUCTIONS\Protocols\US protocol for renal cysts.docx		